




Demodex Blepharitis **L.I.D**

Speaker: Janelle Davison, OD Listen, Identify, Diagnose

Disclosures



Alcon Pharmaceuticals Speaker/Consultant
 Tarsus Pharmaceuticals Speaker/Consultant
 Bausch & Lomb Pharmaceuticals Speaker/Consultant
 Viartis Consultant
 Orasis Pharmaceuticals Speaker/Consultant
 Hilco-Bruder Consultant
 AbbVie Pharmaceuticals Consultant

All conflicts have been mitigated.

About the Speaker



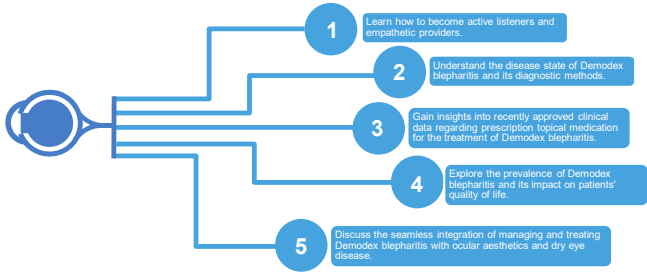

20 years of clinical experience
 16 years Private Practice- "Cold-start"
 Passion for ocular surface disease and ocular aesthetics.
 Heavily involved in optometric community

- Speaker
- Author
- KOL

Tech Software Founder-Paradeyem

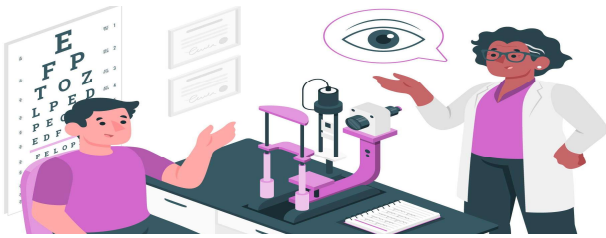
Montego Bay, Jamaica 2023

Learning Objectives



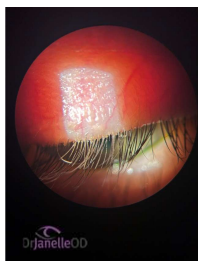Listen


Active Listening Can Enhance Patient Outcomes



Common Symptoms

Active Listening is Essential to Avoid Misdiagnosis



-  RED EYES
-  ITCHY EYES
-  WATERY EYES
-  CRUSTY EYELIDS- WORSE IN THE MORNING

Empathy-Based Care



What is Clinical Empathy?

Julia Simpson, MD, PhD*

Author information · Copyright and License Information · [PMC Disclaimer](#)

The Role of Empathy in Health and Social Care Professionals

Maria Moutafakou 1,2,3,4,5,6,7,8,9,10,11,12,13,14,15,16,17,18,19,20,21,22,23,24,25,26,27,28,29,30,31,32,33,34,35,36,37,38,39,40,41,42,43,44,45,46,47,48,49,50,51,52,53,54,55,56,57,58,59,60,61,62,63,64,65,66,67,68,69,70,71,72,73,74,75,76,77,78,79,80,81,82,83,84,85,86,87,88,89,90,91,92,93,94,95,96,97,98,99,100,101,102,103,104,105,106,107,108,109,110,111,112,113,114,115,116,117,118,119,120,121,122,123,124,125,126,127,128,129,130,131,132,133,134,135,136,137,138,139,140,141,142,143,144,145,146,147,148,149,150,151,152,153,154,155,156,157,158,159,160,161,162,163,164,165,166,167,168,169,170,171,172,173,174,175,176,177,178,179,180,181,182,183,184,185,186,187,188,189,190,191,192,193,194,195,196,197,198,199,200,201,202,203,204,205,206,207,208,209,210,211,212,213,214,215,216,217,218,219,220,221,222,223,224,225,226,227,228,229,230,231,232,233,234,235,236,237,238,239,240,241,242,243,244,245,246,247,248,249,250,251,252,253,254,255,256,257,258,259,260,261,262,263,264,265,266,267,268,269,270,271,272,273,274,275,276,277,278,279,280,281,282,283,284,285,286,287,288,289,290,291,292,293,294,295,296,297,298,299,300,301,302,303,304,305,306,307,308,309,310,311,312,313,314,315,316,317,318,319,320,321,322,323,324,325,326,327,328,329,330,331,332,333,334,335,336,337,338,339,340,341,342,343,344,345,346,347,348,349,350,351,352,353,354,355,356,357,358,359,360,361,362,363,364,365,366,367,368,369,370,371,372,373,374,375,376,377,378,379,380,381,382,383,384,385,386,387,388,389,390,391,392,393,394,395,396,397,398,399,400,401,402,403,404,405,406,407,408,409,410,411,412,413,414,415,416,417,418,419,420,421,422,423,424,425,426,427,428,429,430,431,432,433,434,435,436,437,438,439,440,441,442,443,444,445,446,447,448,449,450,451,452,453,454,455,456,457,458,459,460,461,462,463,464,465,466,467,468,469,470,471,472,473,474,475,476,477,478,479,480,481,482,483,484,485,486,487,488,489,490,491,492,493,494,495,496,497,498,499,500,501,502,503,504,505,506,507,508,509,510,511,512,513,514,515,516,517,518,519,520,521,522,523,524,525,526,527,528,529,530,531,532,533,534,535,536,537,538,539,540,541,542,543,544,545,546,547,548,549,550,551,552,553,554,555,556,557,558,559,560,561,562,563,564,565,566,567,568,569,570,571,572,573,574,575,576,577,578,579,580,581,582,583,584,585,586,587,588,589,590,591,592,593,594,595,596,597,598,599,600,601,602,603,604,605,606,607,608,609,610,611,612,613,614,615,616,617,618,619,620,621,622,623,624,625,626,627,628,629,630,631,632,633,634,635,636,637,638,639,640,641,642,643,644,645,646,647,648,649,650,651,652,653,654,655,656,657,658,659,660,661,662,663,664,665,666,667,668,669,670,671,672,673,674,675,676,677,678,679,680,681,682,683,684,685,686,687,688,689,690,691,692,693,694,695,696,697,698,699,700,701,702,703,704,705,706,707,708,709,710,711,712,713,714,715,716,717,718,719,720,721,722,723,724,725,726,727,728,729,730,731,732,733,734,735,736,737,738,739,740,741,742,743,744,745,746,747,748,749,750,751,752,753,754,755,756,757,758,759,760,761,762,763,764,765,766,767,768,769,770,771,772,773,774,775,776,777,778,779,780,781,782,783,784,785,786,787,788,789,790,791,792,793,794,795,796,797,798,799,800,801,802,803,804,805,806,807,808,809,810,811,812,813,814,815,816,817,818,819,820,821,822,823,824,825,826,827,828,829,830,831,832,833,834,835,836,837,838,839,840,841,842,843,844,845,846,847,848,849,850,851,852,853,854,855,856,857,858,859,860,861,862,863,864,865,866,867,868,869,870,871,872,873,874,875,876,877,878,879,880,881,882,883,884,885,886,887,888,889,890,891,892,893,894,895,896,897,898,899,900,901,902,903,904,905,906,907,908,909,910,911,912,913,914,915,916,917,918,919,920,921,922,923,924,925,926,927,928,929,930,931,932,933,934,935,936,937,938,939,940,941,942,943,944,945,946,947,948,949,950,951,952,953,954,955,956,957,958,959,960,961,962,963,964,965,966,967,968,969,970,971,972,973,974,975,976,977,978,979,980,981,982,983,984,985,986,987,988,989,990,991,992,993,994,995,996,997,998,999,1000

Received: 17 December 2019; Accepted: 25 January 2020; Published: 30 January 2020



Abstract: The current article is an integrative and analytical literature review on the concept and meaning of empathy in health and social care professionals. Empathy, i.e., the ability to understand the personal experience of the patient without bonding with them, constitutes an important communication skill for a health professional, one that includes three dimensions: the emotional, cognitive, and behavioral. It has been proven that health professionals with high levels of empathy operate more efficiently as to the fulfillment of their role in eliciting therapeutic change. The empathetic professional comprehends the needs of the health care team, as the latter feel safe to express the thoughts and problems that concern them. Although the importance of empathy is undeniable, a significantly high percentage of health professionals seem to find it difficult to adopt a model of empathetic communication in their everyday practice. Some of the factors that negatively influence the development of empathy are the high number of patients that professionals have to manage; the lack of adequate time; the brain circuitry within the executive academic culture; but also



Go to: -

Abstract
Patients seek empathy from their physicians. Medical educators increasingly recognize this need. Yet in seeking to make empathy a reliable professional skill, doctors change the meaning of the term. Outside the field of medicine, empathy is a mode of understanding that specifically involves emotional resonance. In contrast, leading physician educators define empathy as a form of detached cognition. In contrast, this article argues that physicians' emotional attachments greatly serve the cognitive goal of understanding patients' emotions. This has important implications for teaching empathy.

8 Tips To Become a Proficient Listener



- Concentrate on the sender
- Listen for intended message
- Refrain from premature judgement
- Reflect and paraphrase
- Ask for clarification
- Maintain focus
- Avoid distractions
- Listen fully before responding



Tanner, K. Long, A. Torrey-Baker T. Active Learning (2004) 2002 Sep 18. In: [SafParks \(Series\)](#). Thousand Oaks (CA): SAGE Publications, 2002. doi:10.4135/9780761941414.ch18



Cultural competence holds a pivotal position in health care and significantly influences the process of active listening.

Tanner, K. Long, A. Torrey-Baker T. Active Learning (2004) 2002 Sep 18. In: [SafParks \(Series\)](#). Thousand Oaks (CA): SAGE Publications, 2002. doi:10.4135/9780761941414.ch18



Identify Demodex Blepharitis

Photo Cred: Janelle Davison, OD


What is Demodex?

Demodex is a microscopic

Feed on oils produced by the skin and eyelashes, which leads to an inflammatory response from the body.

Clinical manifestations of the disease include itching, redness, and crusting of the eyelids that can lead to further complications if left untreated

Collarettes, which are small, whitish deposits that form on the base of the eyelashes, are a diagnostic feature of Demodex blepharitis.




Common Types Of Demodex On Skin

Demodex folliculorum:

- Demodex folliculorum infestation is possibly one of the key contributors in the pathogenesis of MGD related dry eye, and a higher prevalence of chalazion.

Demodex brevis:

- brevis is commonly associated with inflammation.



Diversity of two species of the genus Demodex parasitizing humans

Demodex folliculorum

Demodex brevis

Demodex folliculorum Infestation in Meibomian Gland Dysfunction Related Dry Eye Patients

Abstract: Demodex folliculorum infestation is a common skin condition that has been associated with Meibomian gland dysfunction (MGD) and dry eye disease (DED). The purpose of this study was to determine the prevalence of D. folliculorum infestation in MGD-related DED patients and to evaluate the relationship between D. folliculorum infestation and MGD-related DED. A total of 100 patients with MGD-related DED were recruited for the study. The prevalence of D. folliculorum infestation was found to be significantly higher in MGD-related DED patients compared to healthy controls. The study also found that D. folliculorum infestation was associated with MGD-related DED symptoms, including eye redness, itching, and crusting of the eyelids.

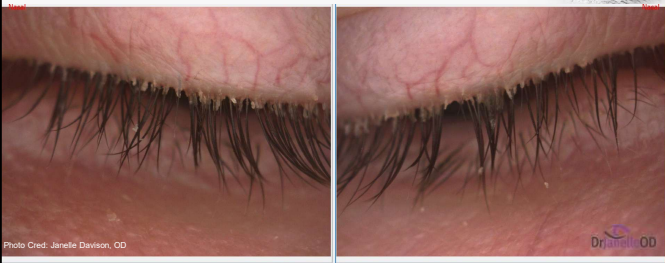Impact of Demodex Blepharitis

In real-world data from the Atlas study: a prospective, multi-center, observational study of 311 patients in the United States to evaluate the impact of Demodex blepharitis¹

80%
of patients reported negative impact on daily activities
N=296

- 47% Feel eyes/conscious of eyes all day
- 47% Difficulty driving at night
- 34% Difficulty wearing makeup
- 30% Additional time needed for daily hygiene routine

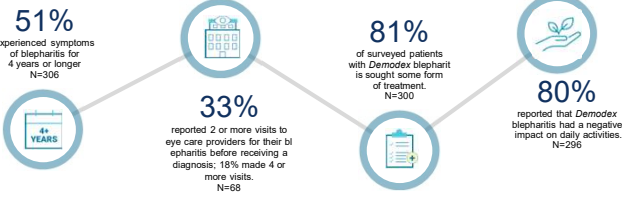
Demodex Blepharitis

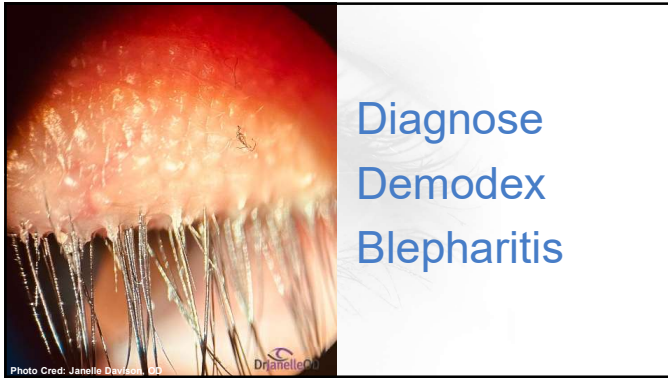

46 WF presented for annual glasses exam reporting blurry vision, itchy eye lids and gritty, and red eyes.

IMPACT & JOURNEY OF DEMODEX BLEPHARITIS

In real-world data from the Atlas study: a prospective, multi-center, observational study of 311 patients in the United States to evaluate the impact of Demodex blepharitis¹





COLLARETTES PATHOGNOMONIC SIGN OF DEMODEX BLEPHARITIS

Collarettes, or cylindrical dandruff, are composed of mite waste products and eggs¹

Collarettes are translucent, solidified exudative excretions that form a cylindrical collar that cuffs around the base of the eyelash follicle²⁻³

Collarettes are displaced along the shaft of the lash as it grows, and they are also displaced due to bacterial overgrowth⁴

Collarettes are composed of regurgitated undigested mite waste combined with epithelial cells, keratin, mite eggs, and secreted proteases and lipases that cause irritation⁵

100% of patients with collarettes have *Demodex* blepharitis^{2,5}

Collarettes at the base of eye lash

Images courtesy of Robert M. M, MD, used with permission⁶

Zhang M, et al. *Ophthalmic Photo Opt*. 2020;40(1):30-42. 3. Gupta N, et al. *Invest Ophthalmol Vis Sci*. 2005;46(2):320-326. 4. Crawford Q, et al. *Optom*. 2010;81(7):42

DEMODEX BLEPHARITIS CAN BE DIAGNOSED DURING SLIT LAMP EXAMINATION

- Collarettes are hardened excretions around the base of the eyelashes visible during slit lamp examination
- Collarettes can be identified when the base of lashes on the upper lid are exposed as the patient looks down
- Collarettes may be missed during a slit lamp exam even with a lid lift if a patient is looking straight ahead

Images courtesy of Elizabeth M. M, MD, used with permission⁷

Patient looking straight ahead Patient looking down, exposing base of lashes and collarettes

Asking a patient to look down during a slit lamp examination can reveal diffuse collarettes and misdirected or missing lashes that are strong signs of *Demodex* blepharitis

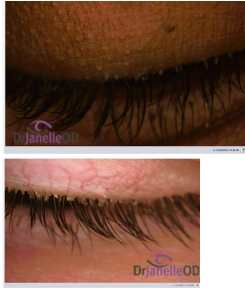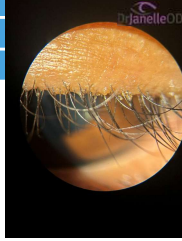
Look Down, Mag-up, and Scan!

Document with photography (not necessary, but great for patient education)

Anterior segment camera

Smart phone adapter

iPhone directly on oculars



Current Therapies

In-office blepharoxfoliation

- BlepHEX
- Zest- Okra based gel
- Nulids Pro

Hypochlorous spray

- Avenova spray

TTO based cleansers

- Terpinen-4-ol (harmful to MGD glands)

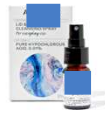Light-Based therapy

- Intense pulse light therapy

Topical 1% Ivermectin cream



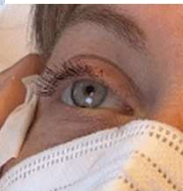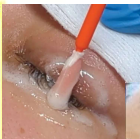
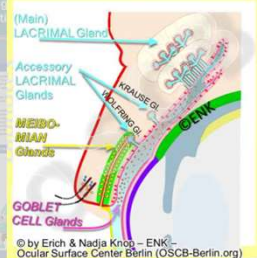
*Ocular irrigation-Rinsada



Current Therapies

Irrigating eyelid retractor after Blepharoxfoliation (BE) is *superior* to BE alone

Glands of the Human Ocular Surface



Case:
 45 WF
 CC-Blurry vision w/igs.
 IOP- OD 11mmHg OS 13mmHg
 SLE:
 +Greater than 10 collarettes
 +Telangiectasia
 +Lid erythema

Failed with in-office blepharoexfoliation & AHT
 TTO-cleanser

Prescribed Lotilaner ophthalmic solution, 0.25% BID OU x 6 weeks.

Post Lotilaner ophthalmic solution 0.25% BID x 6 weeks.

MECHANISM OF ACTION

Lotilaner ophthalmic solution 0.25% (FDA approved)

- Lotilaner functions as a noncompetitive antagonist of mite and arachnid GABA-gated chloride channels^{1,2}
- Directly paralyzes the mite nervous system through parasite-specific GABA inhibition, leading to death^{1,2}
- The lipophilic nature of the drop suggests its ability to flow into the oily sebum of the lash follicle where the mites reside³

Product form⁵
 Preserved (sorbate) multidose eye drop solution in bottle

Dosing⁶
 Twice daily for 6 weeks

1. Chinyereh Credible. Accessed June 26, 2022. <https://www.crediblemeds.com/drugs/lotilaner-ophthalmic-solution>. 2. Corrocheri Salazar R et al. J Ophthalmol. 2023;30(2):261-266. Accessed June 26, 2022. <https://www.ncbi.nlm.nih.gov/pmc/articles/PMC10022222/>. 3. American Academy of Ophthalmology. Accessed June 26, 2022. <https://www.aao.org/eye-health/eye-conditions-and-diseases/blepharitis>. 4. American Academy of Ophthalmology. Accessed June 26, 2022. <https://www.aao.org/eye-health/eye-conditions-and-diseases/blepharitis>. 5. American Academy of Ophthalmology. Accessed June 26, 2022. <https://www.aao.org/eye-health/eye-conditions-and-diseases/blepharitis>. 6. American Academy of Ophthalmology. Accessed June 26, 2022. <https://www.aao.org/eye-health/eye-conditions-and-diseases/blepharitis>.

SATURN-1 and SATURN-2 Studies

Consistent reduction and responses demonstrated in 2 pivotal trials, the largest clinical program for Demodex blepharitis, involving 833 patients

The primary and all secondary endpoints (collarette reduction, mite eradication, lid erythema) met with high statistical significance

Very high responder rate 96%

Efficacy goal
 1^o collarette reduction
 2^o mite eradication,
 2^o redness + collarette cure rate

Safety goal
 Well-tolerated safety profile

OCULAR Adverse Event Summary



low rates of ocular adverse events across both studies

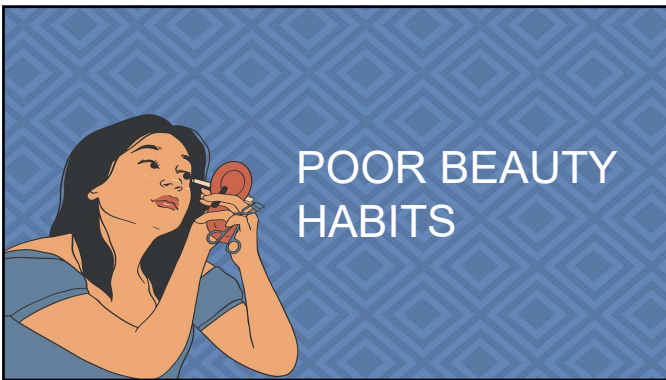
Saturn-1: Treatment-Related Ocular AE Rates $\geq 1\%$ ¹

	Xdemvy (n=212)	Vehicle (n=209)
Instillation Site Pain/Burning/Stinging	25 (11.8%)	16 (7.7%)
Instillation Site Pruritus	3 (1.4%)	7 (3.3%)
Visual Acuity Reduced	3 (1.4%)	5 (2.4%)
Eye Pain	3 (1.4%)	2 (1.0%)
Eye Discharge	3 (1.4%)	1 (0.5%)
Dry Eye	0	1 (0.5%)
AE Severity	All mild	1 moderate All others mild

Saturn-2: Treatment-Related Ocular AE Rates $\geq 1\%$ ²

	Xdemvy (n=203)	Vehicle (n=209)
Instillation Site Pain/Burning/Stinging	16 (7.9%)	14 (6.7%)
Instillation Site Pruritus	1 (0.5%)	1 (0.5%)
Visual Acuity Reduced	1 (0.5%)	3 (1.4%)
Eye Pain	1 (0.5%)	0
Eye Discharge	1 (0.5%)	0
Dry Eye	3 (1.5%)	1 (0.5%)
AE Severity	2 moderate All others mild	1 moderate All others mild

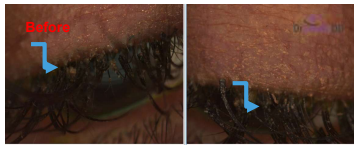
All Adverse Events were mild or moderate



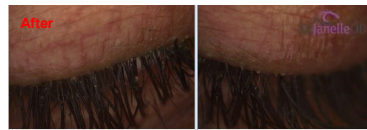
Possible connection of lash extensions and poor beauty trends and increased demodex mites.

Connection:

- Application
 - Ideal environment for mites to thrive.
- Poor make-up hygiene:
 - failure apply and remove make up
 - Infrequent disposable
 - Demodex can live up to 5 days in mascara
 - Shared eye make up



Treatment Lotilaner ophthalmic solution 0.25% BID x 6 wks.



Spatulnikova A, Baranik K, Proszynski T, Proszynski H, Dylisz M. Shared Makeup Cosmetics as a Focus of Demodex folliculorum Infections. Asia Pac J Ophthalmol. 2021; Jan(02):051-6. doi: 10.1097/APJO.0000000000000000. Epub 2021 Jun 18. PMID: 34262972.


In office Removal of Lashes Tool Kit

- Place drop of jojoba or coconut oil on your fingers and massage in lid margin
- Let set for 3-5 minutes
- Apply in-office warming heated mask for 10 minutes
- Use disposable lash brush to begin removing the lashes
- Repeat as needed until lashes are removed
- Send patient home with lid hygiene instructions

 Send back to Lash Artist to Remove with Solvent



DEMODEX BLEPHARITIS KEY TAKE AWAYS



Demodex mites may be present in 69% of all blepharitis cases

Eradicating the root cause (the Demodex mite) rather than just addressing symptoms is crucial

Current options for managing Demodex blepharitis do not eradicate mites

Look for collarettes by having every patient look down, Mag up and scan during a slit lamp examination

Lotilaner ophthalmic solution 0.25% FDA approved therapy is a safe and effective treatment for Demodex blepharitis.

Call to Action

- Look for collarettes during every slit lamp exam - collarettes are the pathognomonic sign of Demodex blepharitis
- Consider Lotilaner as your first line therapy option
- Develop a maintenance plan post-treatment for your patients

Thank you
SM platforms @Drjanelle OD









Connect, Engage, and Message Me On Social
